






HEMATOLOGICAL, SERUM BIOCHEMISTRY, HISTOPATHOLOGICAL AND MUTAGENIC IMPACTS OF TRICLOSAN ON FISH (BIGHEAD CARP)

Rabia Akram¹, Abdul Ghaffar ², Riaz Hussain ^{3,*}, Iahtasham Khan ⁴, Vania Lucia de Assis Santana⁵, Khalid Mehmood ⁶, Saima Naz ⁷, Rehana Iqbal¹, Hafiz Muhammad Imran³, Muhammad Rafi Qamar³ and Hongyun Zhu⁸

¹ Institute of Pure and Applied Biology, Zoology Division, Bhauddin Zakariya University, Multan, Pakistan

² Department of Life Sciences (Zoology), The Islamia University of Bahawalpur-63100, Pakistan

³ Department of Pathology, Faculty of Veterinary and Animal Sciences, The Islamia University of Bahawalpur- 63000, Pakistan

⁴ Section of Epidemiology and Public Health, University of Veterinary and Animal Sciences, Lahore Sub-Campus, Jhang, Pakistan

⁵ National Agricultural Laboratory of Pernambuco, Ministry of Agriculture, Livestock and Food Supply of Brazil, Rua Manoel de Medeiros, s/n, Dois Irmãos, Recife, Pernambuco CEP 52171-030, Brazil

⁶ Department of Clinical Medicine and Surgery, Faculty of Veterinary and Animal Sciences, The Islamia University of Bahawalpur-63000, Pakistan

⁷ Department of Zoology, Government Sadiq College Women University, Bahawalpur, Pakistan

⁸ Key Laboratory of Clinical Veterinary Medicine in Tibet, Tibet Agriculture and Animal Husbandry College, Linzhi 860000 Tibet, People's Republic of China

*Corresponding author: dr.riaz.hussain@iub.edu.pk

ABSTRACT

Agro-aquatic ecosystems are mainly and persistently exposed to a variety of unwanted chemicals and pollutants due to indiscriminate use of agrochemicals such as pesticides, insecticides, heavy metals, germicides, drug residues, industrial wastes, and feed additives. In the present experimental trial, 16 active fish (bighead carp) were randomly kept in four unlike groups (A to D). Blood and serum were obtained on days 5, 10, and 15 of the experiment. For histopathological alterations, fish in every individual group were slaughtered on day 15 of the trial. Mild to moderate different physical ailments like jerking movement, erratic swimming, and mucous secretion from the mouth of fish kept in group D were observed after day 10 of post-exposure. Significantly, lower values of erythrocyte count, Hb, hematocrit while increased values of total white blood cells and neutrophil counts were recorded in fish of groups (C-D). Results on serum chemistry showed a significantly increased quantity of liver functional tests (ALT and AST), renal functional tests (urea and creatinine), and cardiac biomarkers. Results on micronuclei and comet assay indicated increased frequency of DNA damage. The frequency of nuclear and morphological variations in RBCs of fish of group (D) significantly increased compared to the control group. Results on microscopic levels exhibited different histopathological alterations in gills (twisting of secondary lamellae, uplifting of lamellae, lamellar disorganization, necrosis of lamellar epithelial cells), liver (congestion, necrosis of hepatocytes, fatty infiltration), brain (necrosis and atrophy of neuron) and kidneys (necrosis of tubules, increased urinary spaces, tubular necrosis) in treated fish in groups (C-D) after day 10 of post-exposure. From the findings of our experimental research, it can be suggested that triclosan causes toxic effects in bighead carp.

Keywords: Bighead Carp, Triclosan, Blood, Serum, DNA damage, Histopathology

Article History (2020-0722) || Received: 18 Apr 2021 || Revised: 17 Jul 2021 || Accepted: 23 Aug 2021 || Published Online: 30 Aug 2021

1. INTRODUCTION

The existence and destiny of pharmaceutically active compounds in the marine ecosystem seems to be one of the emerging problems in environmental chemistry (Sahu et al. 2018; Ghaffar et al. 2021). Aquaculture itself is also the source of antimicrobial water contamination used in traditional aquaculture to suppress or treat bacterial diseases in aquatic animals (Vijitha et al. 2017). The development of the hydroponics business brought about the exorbitant utilization of antimicrobials to forestall or treat bacterial contaminations in fish and different creatures, especially in non-industrial nations (Bojarski et al. 2020). Antimicrobials are usually prevalent in the environment because of their misuse, overdose, and slow absorption, followed by high water solubility and resistance to

degradation (Limbu et al. 2018). Intensive livestock farming is actually the main aspect of the environmental antimicrobial load, particularly in chickens, goats, pigs, and fish. In lower vertebrates, nearly 24.6 million pounds of antimicrobials are utilizing for non-therapeutic (prevention and growth promotion) uses, compared to only three million pounds for human medical use (Landers et al. 2012). Triclosan [5-chloro-2-(2,4-dichloro-phenoxy) phenol], a broad-spectrum antibacterial chemical, was put on a list of the ten most common terrestrial and aquatic pollutants (Dar et al. 2020). Its widespread use of wastewater treatment plants (WWTPs) of care goods, plastic, fiber, and acrylic products, and inadequate disposal (58-90%) are responsible for its sustained leakage into marine bodies worldwide (Hussain et al. 2019). Since initial successful collection from wastewater, the quantity of triclosan recycling the atmosphere in sewage sludge in the United States. This pesticide can bind to many other suspended substances in marine atmospheres, potentially endangering naval organisms and contributing to further bioaccumulation. Its presence is documented from surface waters, water body sediments, and tissues of many aquatic species, such as algae, freshwater snails, dolphins, mussels, amphibians, including fish (Gatidou et al. 2010; Dhillon et al. 2015). Because of lipophilicity, TCS has the ability for bioaccumulation in the food web and is considered to be detrimental to the environment and life even at low concentrations. Endocrine destruction involves the detrimental effect of TCS on aquatic ecosystems (Tao et al. 2019), neurotoxicity (Sahu et al. 2018), mitochondrial dysfunction (Teplova et al. 2017), oxidative stress (Gyimah et al. 2020) owing to the increased creation of various reactive oxygen species (ROS), variation of the activity of antioxidative, detoxification and impairment of immune system (Park et al. 2017; Mi et al. 2018) were reported. For almost all types of toxins on earth, aquatic bodies are the dumps, but aquatic animals, especially fish, are selected for toxicity tests because they are more sensitive to stressors than terrestrial species, like mammalian organisms (Lackner 1988; Akram et al. 2021). Extended interactions with animals with low, non-fatal, environmentally significant chemical concentrations are of major concern worldwide, with long-term exposures being the subject of regulatory scrutiny. Some clinical studies are available on the sublethal toxicity of TCS in fish, as in trout, (Capkin et al. 2017) *Cyprinus carpio*, *Ctenopharyngodon idella*, and *Cirrhinus mrigala* (Wang et al. 2019; Dar et al. 2020), *Pangasianodon hypophthalmus* (Paul et al. 2020a), Zebrafish (Falisse et al. 2017). However, Fay et al. (2018) suggested that more comparative studies are required because super-class fish are highly complex and a scientific approach to generalization would not be merely based on one or two species. Fish thrive in intimate contact with the natural world and are thus very prone to risks in the marine environment. In their blood and serum parameters, harmful changes in water content are likely to be characterized. Hematological tests are used primarily to analyze the toxicity of triclosan in marine animals, such as fish (Vijitha et al. 2017). Likewise, behavioral alternatives in fish are used in toxicological studies as an indicator of the degree and nature of toxicity (Akram et al., 2021; Sharma et al. 2019). Enzymatic tests such as acetylcholinesterase were already a commonly used biomarker for assessing neurotoxicity and have successfully shown the neurological effects of toxicants in fish (Dutta and Arends 2003; Ghaffar et al. 2021). In addition, information on histological anomalies due to histologic abnormalities are available like the toxicity of TCS in multiple tissues as like the liver, gills, kidneys, brain, and reproductive organs of animals (Gyimah et al. 2020). To assess the acute and chronic toxicity of TCS in bighead carp, a typical aquaculture species in Asia, from a food safety point of view, the above parameters were therefore chosen for the current analysis. To the best of our understanding, however, the toxicity of TCS in freshwater fish is scarce, particularly in Bighead carp. Therefore, we have tried to determine the poisonousness of TCS at sub-lethal doses in bighead carp (*Aristichthys nobilis*) in the current report.

2. MATERIALS AND METHODS

2.1. Fish supervision and preliminary screening tests

Freshwater bighead carp, *Aristichthys nobilis* weighted 150 ± 170 g and 8.5 ± 10 cm in length were collected from a fish farm, district Bahawalpur, Pakistan. For two weeks, fish were accustomed to research laboratory conditions with a continuous stream of de-chlorinated water. The physico-chemical properties of table water were estimated. During the trial, the water temperature varied from 26-28°C, water oxygen saturation ranged from 70 to 100%, pH from 6.5 to 7.5, which were analyzed using a uniform method. All the trial specimens were positioned in crystal aquaria according to the procedure and guidelines of the Bio-Ethics Committee of Islamia University of Bahawalpur.

2.2. Elements

Triclosan (5-chloro-2-(2, 4-dichlorophenoxy) phenol) of up to 98.5% transparency was obtained from commercial Laboratories Pvt Ltd, Punjab, Pakistan. All other chemicals were of analytical ranking and gotten from local marketable sources in Punjab.

2.3. Experimental design and dose exposure

After fourteen days of familiarization, all fish were arbitrarily put in four equal clusters (A-D), without any corporeal aberration, vigorous and free from internal and external parasitic problems. The fish in groups (B-D) was exposed to triclosan at various concentrations. Group A fish operated as a monitoring group. Triclosan was mixed with alcohol and specimen in groups B, C and D were subjected to varying triclosan doses, such as 1000, 1500 and 2500 μ g/L, for 15 days. Various doses of Triclosan were used based on previous reports (Fukuhori et al. 2005; Huang et al. 2018). All fish were carefully scrutinized for any bodily and behavioral signs on a regular basis.

2.4. Hematological assessment and nuclear abnormalities of erythrocytes evaluation

Each fish was held and coated with a thin, dry filter paper and the tail end of its body was blotted with another clean, coarse filter paper. A sharp blade was used to cut the caudal peduncle (control and experimental group) of the fish with a single stroke. After discarding the first blood drop, the free-oozing blood was collected for biochemical analysis. To separate the blood serum that was used for biochemical analysis, blood was centrifuged at 5000rpm for 10min. For hematological criteria, a limited volume of blood was added to the anticoagulant (1% ethylenediamine tetra acetic acid - EDTA). During the sampling process, the blood was mixed thoroughly with the anticoagulant using a thin, blunt glass rod. The whole blood was used in both control and experimental groups for the measurement of erythrocytes, leukocyte counts and hemoglobin.

By using the Neubauer hemocytometer chamber, red blood cells (RBC) and total leukocyte count (TLC) were counted (Islam et al. 2019) at different experimental intervals on 10th of the trial. Estimation of hemoglobin concentration and hematocrit values of fish blood was described previously (Ghaffar et al. 2018), whereas nuclear abnormalities were estimated according to the method described by Hussain et al. (2019) with slight amendment. Nuclear aberrations within cell were graded among thousand cells below 100x magnifications. Erythrocyte indices were calculated as per already defined (Khan 2009).

2.5. Enzymatic assessments and histological evaluations

For various serological criteria, serum was parted from the blood of individually fish placed on the frost at various investigational periods on 10th day of the experiment. A chemistry analyzer was used to evaluate different serum biochemical parameters using widely available kits (Randox Company Pvt), as well as ALT and AST, urea, creatinine and cholesterol, and triglycerides. On 10th day of the experiment, 05 fish from every group were arbitrarily scored, slain and dichotomized to estimate histopathological modifications. Various organs, as the liver gills and kidneys, were extracted, pondered and stored in a 10% formaldehyde solution. Histopathological studies of multiple organs, with the gills, liver and kidneys, were executed on 10th day of the research. Visceral processing done by using Hematoxylin and Eosin staining techniques for histopathological changes (Hussain et al. 2019).

2.6. Statistical analysis

In this report, the collected data is described as mean \pm SE. Normally, the composed data was disseminated in every group and statistical analysis was took placed by one-way analysis of variance (ANOVA), Using IBM SPSS software (Version 20). The variance in the control and treatment clusters was resolute by the Tukey test at P<0.05.

3. RESULTS

3.1. Nuclear abnormalities of erythrocytes

The findings of the percentile rate of various physical and nuclear alterations in of fish exposed to various concentrations of triclosan are accessible in Table 1. The fish exposed to triclosan (1500 and 2500 μ g/L) showed an elevated occurrence of multiple morphological defects in red blood cells. The percentile rate of erythrocytes (Pear designed), spherocytes and microcytes (Fig. 1) in fish exposed to 1500 and 2500 μ g/L concentrations was significantly higher at 10th day of the trial relative to control groups. In RBCs of fish exposed to 1000, 1500 and 2500 μ g/L triclosan, the percentile rate of different changes in nucleus such as notched and blebbed micronuclei and broken nuclei was significantly increased in fish compared to the rheostat group (Table 2). Results exhibited that the percentile rate of erythrocytes with fragmented nuclear parts and erythrocyte with nuclear leftovers was knowingly higher in fish exposed to 1500 and 2500 μ g/L triclosan at 10th day of the experiment in comparison to untreated control fish (Fig. 1).

3.2. Hematological studies and serum analysis

Consequences from the changed hematological constraints of fish blood cells showing to varying amounts of triclosan are accessible in the (Table 2). Over last 10th day of the experiment, fish showing to 1500 and 2500 μ g/L of triclosan (groups C and D) showed a significant reduction in red blood cell count. Concentration of hemoglobin was reduced significantly in fish blood exposed to (1500 and 2500 μ g/L) higher concentrations of triclosan at 10th day of

experiment. Fish exposed to 1000, 1500 and 2500µg/L of triclosan exhibited that the number of differential leukocytes (neutrophilic leukocytosis) was significantly increased on 10th day of the experiment (Table 3).

The findings revealed that, relative to untreated control fish, lymphocytes, monocytes were substantially reduced in fish showed to 1500 and 2500µg/L of triclosan on 10th day of the experiment. In fish exposed to higher concentrations (1500 and 2500µg/L) of triclosan on 10th day of the trial, the number of packed blood cells was also significantly reduced. The findings of various serum biochemical parameters in fish exposed to different triclosan concentrations are presented below (Table 4). On 10th day of the trail, the quantity of serum albumin and overall serum protein substantially reduced in fish (Groups C and D) subjected to 1500 and 2500µg/L of triclosan when related to control group fish.

Table 1: Percentile rate of various morphological and nuclear alterations erythrocytes of bighead carp induced by triclosan

Parameters/days	Groups/Treatments			
	A (0.0µg/L)	B (1000µg/L)	C (1500µg/L)	D (2500µg/L)
Pear shaped erythrocyte (%)				
5	0.65±0.01	0.65±0.01	0.67±0.01	0.68±0.01
10	0.61±0.07	0.67±0.01	0.68±0.03	0.71±0.07
15	0.62±0.05	0.68±0.04	0.69±0.01	3.25±1.01*
Spherocytes (%)				
5	0.42±0.08	0.45±0.02	0.47±0.01	0.48±0.01
10	0.44±0.06	0.45±0.04	0.47±0.03	0.49±0.03
15	0.45±0.07	0.46±0.03	0.48±0.05	2.21±0.09*
Microcytes (%)				
5	0.27±0.01	0.28±0.03	0.29±0.06	0.30±0.02
10	0.26±0.03	0.27±0.05	0.29±0.03	0.32±0.03
15	0.27±0.05	0.28±0.07	2.69±0.03*	2.92±0.08*
Erythrocyte with broken nucleus (%)				
5	0.34±0.03	0.36±0.07	0.36±0.03	0.37±0.05
10	0.37±0.05	0.37±0.05	0.38±0.03	0.39±0.07
15	0.36±0.04	0.39±0.04	0.59±0.05*	0.88±0.09*
Erythrocyte with micronucleus (%)				
5	0.22±0.04	0.25±0.03	0.28±0.02	0.29±0.01
10	0.23±0.05	0.26±0.05	0.29±0.03	0.30±0.01
15	0.24±0.04	0.27±0.02	1.43±0.39*	1.97±0.08*

Values (Mean±SE) with asterisks in a row differ significantly (P<0.05) from untreated fish. Triclosan is antibacterial chemical among 10 most common terrestrial and aquatic pollutants.

Table 2: Hematological profile bighead carp exposed to different concentration of induced by triclosan

Parameters/days	Groups/Treatments			
	A (0.0µg/L)	B (1000µg/L)	C (1500µg/L)	D (2500µg/L)
Erythrocyte counts				
5	3.31±0.01	3.30±0.11	3.28±0.03	3.27±0.13
10	3.33±0.10	3.29±0.10	3.26±0.03	3.24±0.09
15	3.37±0.13	3.29±0.13	2.57±0.03*	2.44±0.19*
Hemoglobin (g/dl)				
5	10.12±0.14	10.04±0.11	9.99±0.24	9.15±0.11
10	10.15±0.11	10.02±0.19	9.79±0.33	9.70±0.13*
15	10.22±0.71	10.05±0.17	8.78±0.11*	7.11±0.01*
White blood counts				
5	16.8±0.35	17.1±0.36	18.8±0.51	19.1±0.11
10	16.9±0.31	17.4±0.48	18.8±0.79	19.8±0.06*
15	16.9±0.38	17.6±0.34	20.7±0.99*	22.6±0.61*
Pack cell volume				
5	36.4±0.31	35.5±0.53	33.2±0.38	31.3±0.43
10	37.1±0.12	34.3±0.61	31.5±0.43*	29.1±0.11*
15	36.9±0.33	34.1±0.11	29.1±1.10*	28.1±1.01*
Neutrophils (%)				
5	23.3±0.28	23.8±0.31	24.5±0.11	25.2±0.13
10	23.5±0.33	24.1±0.11	25.0±0.07	26.99±0.82*
15	22.9±0.25	24.2±0.22	28.1±0.33	29.7±0.55*

Values (Mean±SE) with asterisks in a row differ significantly (P<0.05) from untreated fish.

Table 3: Different serum biochemistry parameters of bighead carp exposed to different concentrations of triclosan

Parameters/days	Groups/Treatments			
	A (0.0µg/L)	B (1000µg/L)	C (1500µg/L)	D (2500µg/L)
Total proteins (mg/dL)				
5	3.34±0.03	3.33±0.02	3.31±0.02	3.18±0.05
10	3.35±0.04	3.24±0.02	3.11±0.05	3.01±0.01
15	3.36±0.02	3.25±0.04	2.81±0.10*	2.25±0.05*
Aspartate aminotransferase (U/L)				
5	11.7±0.13	12.1±0.11	13.15±0.16	14.11±0.13
10	11.4±0.15	12.6±0.12	14.22±0.22	14.55±0.33
15	11.5±0.11	12.8±0.21	16.35±0.33*	17.11±0.44*
Alanine aminotransferase (U/L)				
5	18.87±0.17	19.12±0.23	20.11±0.12	21.4±0.13
10	18.93±0.33	20.11±0.17	21.9±0.13	23.1±0.05
15	19.65±0.26	21.1±0.11	25.5±0.78*	26.2±0.17*
Urea (mg/dL)				
5	7.11±0.03	7.14±0.11	8.19±0.22	8.33±0.11
10	8.01±0.02	8.13±0.19	9.33±0.33	9.752±0.31
15	7.09±0.09	8.14±0.03	9.99±0.31*	10.5±0.22*
Creatinine (mg/dL)				
5	1.18±0.03	1.25±0.02	1.29±0.01	1.30±0.03
10	1.19±0.08	1.27±0.10	1.30±0.03	1.32±0.01
15	1.18±0.09	1.29±0.09	1.65±0.01*	1.74±0.05*
Cholesterol (mg/dL)				
5	132.4±2.11	135.3±1.22	141.3±1.37	143.1±1.9
10	135.1±2.15	137.7±2.13	142.1±1.22	144.1±1.15
15	137.3±2.01	138.6±2.19	149.1±3.11*	153.1±2.23*
Triglycerides (mg/dL)				
5	155.4±5.11	156.2±3.55	159.5±3.13	160.3±2.11
10	157.3±4.15	158.5±2.85	161.1±2.91	162.3±1.55
15	156.5±3.15	159.5±1.89	169.1±3.33*	172.7±2.29*

Values (Mean±SE) with asterisks in a row differ significantly (P<0.05) from untreated fish

Table 4: Severity of various microscopic alterations in different visceral tissues of bighead carp treated with triclosan

Organs/Histopathological lesions	Groups/Treatments		
	B (1000µg/L)	C (1500µg/L)	D (2500µg/L)
Liver			
Pyknosis	+	++	+++
Vacuolar degeneration	++	++	++++
Degeneration of hepatocyte	++	++	+++
Hemorrhages	+	+++	++++
Kidneys			
Deterioration of glomerulus	+	++	+++
Necrosis of tubular cells	+	++	++++
Congestion	+	+++	+++
Increased Bowman's space	+	++	++++
Ceroid formation	+	++	+++
Brain			
Necrosis of neurons	+	++	+++
Congestion of neural cells	-	++	++
Intracellular oedema	+	++	++
Cytoplasmic vacuolization	++	+++	+++
Atrophy of neuron	+	++	+++
Gills			
Necrosis of lamellar epithelial cells	+	++	+++
Disruption of primary lamellae	+	+++	++++
Congestion	+	++	+++
Congested cartilaginous core	+	++	++
Lamellar atrophy	++	++	+++
Lamellar disorganization	++	+++	+++

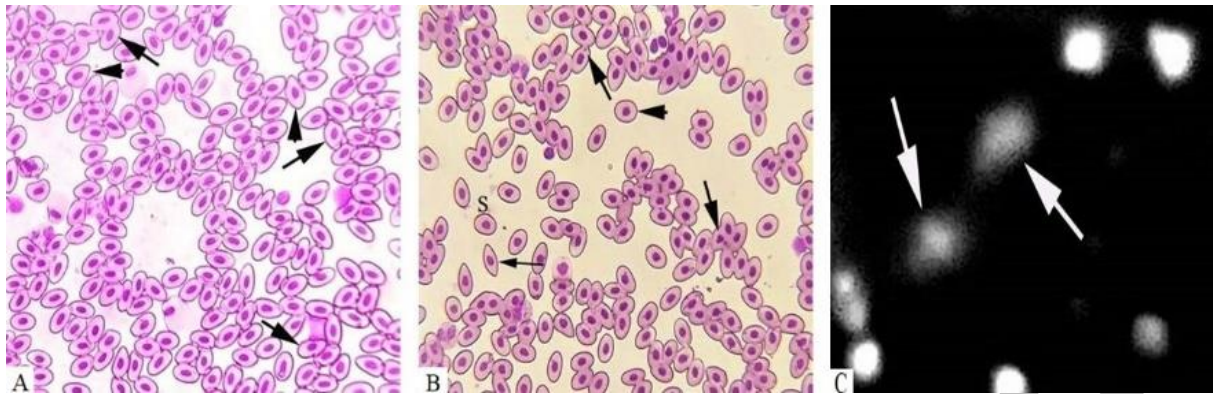


Fig. 1: Photomicrograph showing different morphological and nuclear alterations along with DNA damage in bighead carp treated with triclosan (1500 and 2500µg/L). A) Erythrocyte with condensed nuclei (arrows) and pear shape erythrocytes (arrow heads), B) erythrocytes with micronuclei (thick arrows), spindle shape erythrocytes (thin arrows) and spherical erythrocyte (arrowhead) and C) comet assay showing DNA damage of lymphocytes (arrows). Geimsa Stain. 1000X.

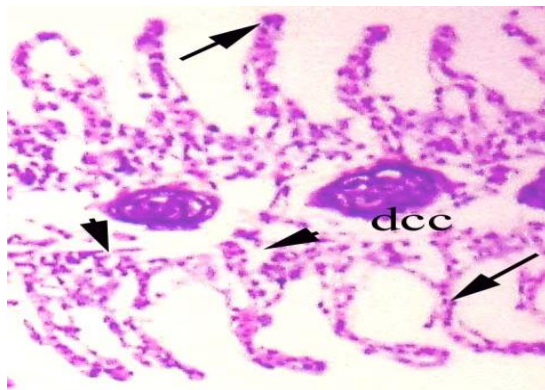


Fig. 2: Photomicrograph of gills tissues of fish treated with Triclosan (2500µg/L) showing disorganization of secondary lamellae (arrow heads), necrosed lamellar pillar cells (arrows) and disorganization of cartilaginous core (dcc). H & E. 400X.

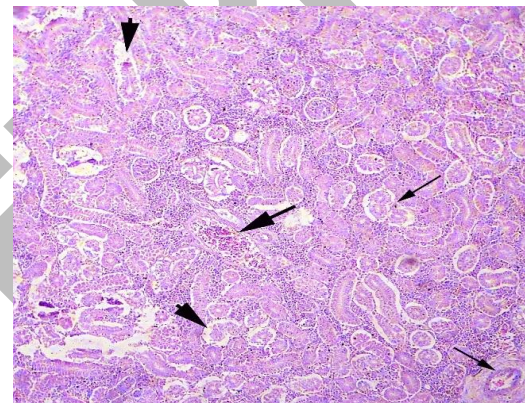


Fig. 3: Photomicrograph of kidneys of fish treated with Triclosan (2500µg/L) showing necrosis of renal tubules (thin arrows), congestion (thick arrows) and degeneration of tubules (arrow heads). H & E.200X.

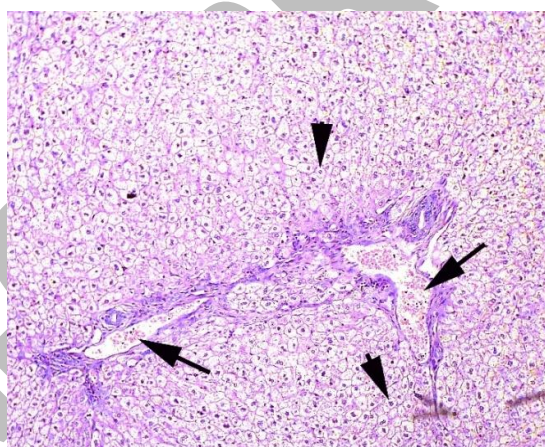


Fig. 4: Photomicrograph of liver of fish treated with Triclosan (2500µg/L) showing congestion (arrows) and necrosis (arrow heads). H & E. 200X.

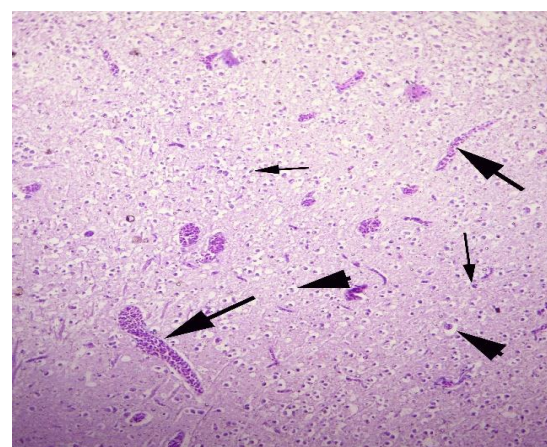


Fig. 5: Photomicrograph of brain of fish treated with Triclosan (2500µg/L) showing various microscopic lesions congestion (arrows), necrosis of neurons (thin arrows) and atrophy of neuron (arrow heads). H & E.200X.

The amount of serum alanine aminotransferase (ALT) and serum aspartate aminotransferase (AST) and serum alkaline phosphatase (ALP) suggestively raised in fish liver tissue at higher triclosan concentrations (1500 and 2500 $\mu\text{g/L}$) on 10th day of the experiment (Table 3). Serum triglycerides in fish treated to 1000, 1500 and 2500 $\mu\text{g/L}$ were significantly raised on last 10th day of the trail. The amount of urea and creatinine significantly enhanced compared to control fish kidneys, exposed to 1500 and 2500 $\mu\text{g/L}$ of triclosan at 10th day of the experiment. In treated groups (B-D) fish exposed to 1000, 1500 and 2500 $\mu\text{g/L}$ the glucose level significantly increased on 10th day of the study. Cholesterol and lactate dehydrogenase significantly raised in fish exposed to 1500 and 2500 $\mu\text{g/L}$ of triclosan relative to control fish (Table 3).

3.3. Histopathology

Histopathological alterations in various fish tissues exposed to different doses of triclosan are shown in Table 4. Severe histopathological abnormalities in gill tissues of fish such as disorganization of lamellae, necrosed lamellar pillar (Fig. 2), primary lamellar disintegration, curling and fusion of secondary lamellae, extreme congestion and worsening of cartilaginous cores were observed in groups C and D of trail. Curling, uplifting of epithelial cells of secondary lamellae were generally reported in C and D clusters of 10th day trail. In the kidneys of chemical treated groups (B-D), there were seen mild to moderate histopathological changes like pyknosis, deterioration, congestion, elevation in Bowman's capsule, edema, tubular epithelial disintegration, melanomacrophage accumulation and luminal atrophy were observed (Fig. 3). Major histopathological changes were appeared in the kidneys of fish in B group at 10th day of experiment, such as glomerular degradation, necrosis of tubular cells. Medium to extreme histopathological changes in the liver tissues of fish, namely congestion (Fig. 4), cirrhosis, hemorrhage, karyorrhexis, karyolysis, hypertrophy of nucleus and eccentric nucleus, fragmented vacuole fragmentation was noted on 10th day of the experiment. Various histopathological liver problems in fish (*Aristichthys nobilis*) exposed to doses of 1500 and 2500 $\mu\text{g/L}$ showed vacuolar disintegration, karyorrhexis, karyolysis on 10th day of the research investigation. Results on brain histopathology exhibited different microscopic lesions like congestion, necrosis and atrophy of neuron (Fig. 5) in triclosan treated fish.

4. DISCUSSION

Triclosan is a popular ingredient in a variety of everyday cleaning products, including hand soaps, dish and laundry soaps, and personal care products like toothpaste and mouthwash, and can be found in institutional, clinical, commercial, and residential settings. These substances can be flushed down the drain, survive wastewater treatment, and end up in rivers. Because triclosan is lipophilic, it is rapidly absorbed and bioaccumulated in fatty tissues, particularly in aquatic species. Fish have been shown to collect substantial amounts of Triclosan metabolites, according to studies. Due to triclosan, a significantly higher frequency of various morphological ailments in red blood cells of bighead carp was observed, including microcytes, leptocytes, spherocytes, pear-shaped and various nuclear aberrations such as lobed, blebbed and notched nucleus, erythrocyte with micronucleus, vacuolated nucleus, nuclear ruminants in red blood cells. Previously, similar results like formation of micronucleus along with lobed, blebbed, notched, irregular and apoptotic nucleus in fish *Oreochromis niloticus* (Vijitha et al. 2017) exposed to sublethal dose of triclosan was reported. Moreover, similar reports on erythrocytic abnormalities in American bullfrog, *Lithobates catesbeianus* (Curi et al. 2019), Rain bow trout *Labio rohita* (Jindal and Verma 2015) and rats and Hamsters (Rodricks et al. 2010; Environment and Climate Change Canada Health Canada, 2016), were observed in previous reports. The blood of fish subjected to various dosages of triclosan was tested for reduced haemoglobin content, monocytes, lymphocytes, and pack cell volume. Due to fast oxidation of haemoglobin, hemolysis, and erythrocyte deterioration, parameter values are reduced (Ghaffar et al. 2016; Gul et al. 2017). Rise in the number of neutrophils may rise also be attributed to immunological reactions shown by tissue grievance in exposed bighead carp. In one of the previous reports, decreased RBC and hemoglobin and this was due to hemolyzing capacity of triclosan and rapid oxidation of hemoglobin to methemoglobin. However, WBC content was significantly increased owing to leucocyte mobilization, as the defensive mechanism of fish *Oreochromis niloticus* (Vijitha et al. 2017) exposed to different concentration of triclosan. Moreover, similar reports like significant decrease in hematological parameters related to complete blood counts except for TLC, mean corpuscular hemoglobin concentration (MCHC) and red cell distribution width (RDW) were studied in *Pangasianodon* fish (Sahu et al. 2018; Paul et al. 2020b) exposed to different doses of triclosan. However, significant ($P < 0.05$) decrease in hemoglobin (Hb) content, RBC, hematocrit and mean corpuscular volume (MCV) in triclosan exposed fish, which indicates the disruptive action of triclosan on erythropoietic tissues, caused shrinkage in red blood cells and making the erythrocytes more brittle and porous. Whereas significant ($P < 0.05$) increase in TLC, mean corpuscular hemoglobin (MCH) and MCHC indicates the direct or indirect responses of structural damage in RBC membranes resulting in hemolysis in fish *Labio rohita* exposed to different doses of triclosan (Geetha and Priya 2020).

In the current study, serum biochemical markers (ALT, AST, and ALP) significantly increased in response to triclosan-induced stress. Serum biochemical indicators such as serum albumin amount and serum total protein were shown to be lower in fish blood in the current study. However, stress circumstances in treated fish resulted in elevated glucose, cholesterol, and lactate dehydrogenase levels were studied. Serum creatinine and uric acid are very essential factors for muscle and purine metabolism of kidney performance (Akram et al. 2021). The quantity of urea and creatinine in the liver and kidney were also enhanced, reflecting disruption of filtration mechanisms and damage to the kidneys and liver tissues of fish exposed to triclosan in the current experiment. Previously, change in serum lysozyme activity (enzymatic activity), total immunoglobulin in serum, ceruloplasmin level, serum total protein, albumin and globulin quantity in fish *Pangasianodon hypophthalmus* (Bera et al. 2020) was evident in TCS exposed groups in comparison to control during the experimental periods. However, in *Cyprinus carpio* (Tasneem and Yasmeen 2020), total glycogen, SDH and LDH significantly reduced as the days of sub-lethal exposure of triclosan increased in fish was reported. Similar reports were observed in *Channa punctatus* (Agrahari et al. 2007), *Labeo rohita* (Ghaffar et al. 2021), *Rhamdia quelen* (Banaee and Ahmadi 2011), *Oreochromis niloticus* (Banaee and Ahmadi 2011), exposed to toxicant. In the present research work, histopathological lesions in bighead carp liver tissue were congestion, cytoplasmic volume reduction, expanded sinusoidal space, hepatocyte karyolysis, and necrosed tissues of liver subjected to higher triclosan concentrations. Previously, histological alterations in liver of tadpole larvae of frog *Bufo gargarizans* (Chai et al. 2017) exposed to different doses of triclosan was reported. Previously, triclosan-exposed necrotic hepatocytes in the liver (Capkin et al. 2017). Histopathological alterations in the liver of *Catla catla* (Hemalatha et al. 2019) fish subjected to various triclosan concentrations were also investigated. Similar findings, such as swelling, epithelial elevating, and lamellar fusion, were also observed, along with hepatocyte vacuolation, nuclear pyknosis, and hepatocyte vacuolation, nuclear pyknosis, hepatocytic degeneration, sinusoid extension, and hemorrhage in *Oncorhynchus mykiss* (Rodrigues et al. 2019), *Barbonymus gonionotus* (Islam et al. 2015) were reported in previous studies. In current trial, microscopic lesions such as edema, cirrhosis, glomerular deterioration, Bowman's space, tubule congestion and luminal atrophy were also seen in the kidneys of treated fishes. Previously, Regeneration of damaged epithelial cells, edema, glomerular degeneration was observed in *Oreochromis nilotica* (Augusto et al. 1996), *Opsanus tau* (Reimschuessel et al. 1996), *Carassius auratus* (Reimschuessel and Williams 1995), exposed to toxicants. Presently, Because the gills have direct contact with water pollutants and are the first organ into which contaminants penetrate, literature has shown that the development of histopathological changes in fish gills is a very effective tool for measuring the impact of various pollutants in the freshwater environment. Gills are those essential organs that serve as a gas exchange medium, boundary between water and fish, balancer of ionic compounds and are responsible for the process of osmoregulation (Ghaffar et al. 2018). In the current research, histopathological lesions in fish gills include atrophy, fusion, uplifting, obstruction, and primary secondary lamellae disorganization. Previously, related histological alterations were observed in zebrafish (O'Brown et al. 2018) exposed to sublethal doses of toxicant. The literature contains limited information on the effect of antibacterial chemical on the biochemical analysis in profile of freshwater fish of their use as biomarkers of contamination (Hussain et al. 2019). The results of this research have shown that triclosan contaminants are likely to have adversely affected the fish. Therefore, to verify these findings, more exploratory work needs to be done.

Conclusion: The findings showed that triclosan changes the hematological, histopathological, and biochemical parameters of the fish *A. nobilis* at sublethal concentrations, and that these parameters can be used to detect triclosan adverse effects in aquatic environments and to determine the physiological condition of fish. As a result, histopathological examinations are carried out to determine the extent of damage to key organs such as the liver, kidneys, and gills. The introduction of such chemicals into rivers, on the other hand, should be limited, despite the fact that carps (*A. nobilis*) are natural occupants of freshwater habitats and are a sought-after food species in nations like Pakistan. However, more research work is required to verify these findings.

Author's Contribution: RA, AG and RH designed and executed the research. IK, KM, SN, HMI and MRQ involved in interpretations of results and manuscript preparation. VLDAS, RI, RA, RH and HZ wrote the paper.

Acknowledgement: All the authors acknowledge Assistant Director Fish breeding and hatchery center district Bahawalpur for providing test specimens for this trial.

ORCID

Abdul Ghaffar <https://orcid.org/0000-0002-5608-785X>
Riaz Hussain <https://orcid.org/0000-0003-3058-1371>

Iahtasham Khan <https://orcid.org/0000-0003-2134-5545>
Khalid Mehmood <https://orcid.org/0000-0003-4720-8792>
Saima Naz <https://orcid.org/0000-0002-7748-0490>

REFERENCES

- Agrahari S, Pandey KC and Gopal K, 2007. Biochemical alteration induced by monocrotophos in the blood plasma of fish, *Channa punctatus* (Bloch). *Pesticide Biochemistry and Physiology* 88: 268-272. <https://doi.org/10.1016/j.pestbp.2007.01.001>
- Akram R, Iqbal R, Hussain R, Jabeen F and M Ali, 2021. Evaluation of Oxidative stress, antioxidant enzymes and genotoxic potential of bisphenol A in fresh water bighead carp (*Aristichthys nobilis*) fish at low concentrations. *Environmental Pollution* 268 (Part A): 115896. <https://doi.org/10.1016/j.envpol.2020.115896>
- Augusto J, Smith B, Smith S, Robertson J and Reimschuessel R, 1996. Gentamicin-induced nephrotoxicity and nephroregeneration in *Oreochromis nilotica*, a tilapia fish. *Diseases of Aquatic Organisms* 126: 49-58. <https://doi.org/10.3354/dao026049>
- Banaee M and Ahmadi K, 2011. Sub-lethal toxicity impacts of endosulfan on some biochemical parameters of the freshwater crayfish (*Astacus leptodactylus*). *Research Journal of Environmental Sciences* 5: 827-835. <https://doi.org/10.3923/rjes.2011.827.835>
- Bera KK, Kumar S, Paul T, Parasad KP, Shukla SP and Kumar K, 2020. Triclosan induces immunosuppression and reduces survivability of striped catfish *Pangasianodon hypophthalmus* during the challenge to a fish pathogenic bacterium *Edwardsiella tarda*. *Environmental Research* 186: 109575. <https://doi.org/10.1016/j.envres.2020.109575>
- Bojarski B, Kot B and Witeska M, 2020. Antibacterial in aquatic environment and their toxicity to fish. *Pharmaceuticals* 13: 189. <https://doi.org/10.3390/ph13080189>
- Capkin E, Ozecelep T, Kayis S and Altinok I, 2017. Antimicrobial agents, triclosan, chloroxylenol, methylisothiazolinone and borax in cleaning had genotoxic and histopathologic effects on rainbow trout. *Chemosphere* 182: 720-729. <https://doi.org/10.1016/j.chemosphere.2017.05.093>
- Chai L, Chen A, Luo P, Zhao H and Wang H, 2017. Histopathological changes and lipid metabolism in the liver of *Bufo gargarizans* tadpoles exposed to triclosan. *Chemosphere* 182: 255-266. <https://doi.org/10.1016/j.chemosphere.2017.05.040>
- Curi LM, Peltzer PM and Sandoval MT and Lajmanovich RC, 2019. Acute toxicity and sublethal effects caused by a commercial herbicide formulated with 2,4-D on *Physalaemus albonotatus* tadpoles. *Water, Air, & Soil Pollution* 230: Article number # 22. <https://doi.org/10.1007/s11270-018-4073-x>
- Dar OI, Sharma S and Singh K, Sharma A, Bhardwaj R and Kaur A, 2020. Biomarkers for the toxicity of sublethal concentrations of triclosan to the early life stages of carps. *Scientific Reports* 10: 17322. <https://doi.org/10.1038/s41598-020-73042-y>
- Dhillon GS, Dhillon GS, Kaur S, Pulicharla R, Brar SK, Cledón M, Verma M and Surampalli RY, 2015. Triclosan: current status, occurrence, environmental risks and bioaccumulation potential. *International Journal of Environmental Research Public Health* 12: 5657-5684. <https://doi.org/10.3390/ijerph120505657>
- Dutta HM and Arends DA, 2003. Effects of endosulfan on brain acetylcholinesterase activity in juvenile bluegill sunfish. *Environmental Research* 91: 157-162. [https://doi.org/10.1016/S0013-9351\(02\)00062-2](https://doi.org/10.1016/S0013-9351(02)00062-2)
- Falisse E, Voisin AS and Silvestre F, 2017. Impact of triclosan exposure on zebrafish early-life stage: toxicity and acclimation mechanisms. *Aquatic Toxicology* 189: 97-107. <https://doi.org/10.1016/j.aquatox.2017.06.003>
- Fay K, LaLone C, Feifarek D, Doering J, Cavallin J, Villeneuve Dan, Glaberman S and Ankleley G, 2018. Addressing species diversity in biotransformation: variability in expressed transcripts of hepatic biotransformation enzymes among fishes. SETAC Europe, Rome, Italy, May 13-17, 2018.
- Fukuhori N, Kitano M and Kimura H, 2005. Toxic effects of bisphenol A on sexual and asexual reproduction in *Hydra oligactis*. *Archives of Environmental Contamination and Toxicology* 48: 495-500. <https://doi.org/10.1007/s00244-004-0032-1>
- Gatidou G, Vassalou E and Thomaidis NS, 2010. Bioconcentration of selected endocrine disrupting compounds in the Mediterranean mussel *Mytilus galloprovincialis*. *Marine Pollution Bulletin* 60: 2111-2116. <https://doi.org/10.1016/j.marpolbul.2010.07.003>
- Geetha N and Priya N, 2020. Impact of triclosan an antimicrobial agent on haematological parameters of fresh water fish *Labeo rohita*. *International Journal of Applied Research* 6: 118-123.
- Ghaffar A, Hussain R, Abbas G, Kalim M, Khan A, Ferrando S, Gallus L and Ahmad Z, 2018. Fipronil (Phenylpyrazole) induces hemato-biochemical, histological, and genetic damage at low concentrations in common carp, *Cyprinus carpio* (Linnaeus, 1758). *Ecotoxicology* 27: 1261-1271. <https://doi.org/10.1007/s10646-018-1979-4>
- Ghaffar A, Hussain R, Ahmad N, Ghafoor R, Akram MW, Khan I and Khan A, 2021. Evaluation of hemato-biochemical, antioxidant enzymes as biochemical biomarkers and genotoxic potential of glyphosate in freshwater fish (*Labeo rohita*). *Chemistry and Ecology* 37: 646-667. <https://doi.org/10.1080/02757540.2021.1937141>
- Ghaffar A, Hussain R, Aslam M, Abbas G and Khan A, 2016. Arsenic and urea in combination alters the hematology, biochemistry and protoplasm in exposed Rahu fish (*Labeo rohita*) (Hamilton, 1822). *Turkish Journal of Fisheries and Aquatic Sciences* 16: 289-296. http://dx.doi.org/10.4194/1303-2712-v16_2_09
- Gul ST, Khan A, Farooq M, Niaz S, Ahmad M, Khatoun A, Hussain R, Saleemi MK and Hassan MF, 2017. Effect of sub lethal doses of thiamethoxam (a pesticide) on hemato-biochemical values in cockerels. *Pakistan Veterinary Journal* 37: 135-138.

Akram R, Ghaffar A, Hussain R, Khan I, Santana VLDA, Mehmood K, Naz S, Iqbal R, Imran HM, Qamar MR and Zhu H, 2021. Hematological, serum biochemistry, histopathological and mutagenic impacts of triclosan on fish (bighead carp). *Agrobiological Records*. <https://doi.org/10.47278/journal.abr/2021.009>

- Gyimah E, Dong X, Qiu W, Zhang Z and Xu H, 2020. Sublethal concentrations of triclosan elicited oxidative stress, DNA damage, and histological alterations in the liver and brain of adult zebrafish. *Environmental Science and Pollution Research* 27: 17329–17338. <https://doi.org/10.1007/s11356-020-08232-2>
- Hemalatha D, Rangasamy B, Nataraj B and Ramesh M, 2019. Assessment of triclosan impact on enzymatic biomarkers in an Indian major carp, *Catla catla*. *The Journal of Basic and Applied Zoology* 80: Article # 23. <https://doi.org/10.1186/s41936-019-0094-2>
- Huang TH, Wang PW, Yang SC, Chou WL and Fang JY, 2018. Cosmetic and therapeutic applications of fish oil's fatty acids on the skin. *Marine Drugs* 16: 256. <https://doi.org/10.3390/md16080256>
- Hussain R, Ali F, Javed MT, Jabeen G, Ghaffar A, Khan I, Liaqat S, Hussain T, Abbas RZ, Riaz A, Gul ST and Ghori MT, 2019. Clinico-hematological, serum biochemical, genotoxic and histopathological effects of trichlorfon in adult cockerels. *Toxin Reviews*. <https://doi.org/10.1080/15569543.2019.1673422>
- Islam MJ, Rasul MG, Kashem MA, Hossain MM, Liza AA, Sayeed MA and Hossain MM, 2015. Effect of oxytetracycline on Thai silver barb (*Barbonymus gonionotus*) and on its culture environment. *Journal of Fisheries and Aquatic Science* 10: 323–336. <https://doi.org/10.3923/jfas.2015.323.336>
- Islam SMM, Rahman MA, Nahar S, Uddin MH, Haque MM and Shahjahan M, 2019. Acute toxicity of an organophosphate insecticide sumithion to striped catfish *Pangasianodon hypophthalmus*. *Toxicology Reports* 6: 957–962. <https://doi.org/10.1016/j.toxrep.2019.09.004>
- Jindal R and Verma S, 2015. In vivo genotoxicity and cytotoxicity assessment of cadmium chloride in peripheral erythrocytes of *Labeo rohita* (Hamilton). *Ecotoxicology and Environmental Safety* 118: 1–10. <https://doi.org/10.1016/j.ecoenv.2015.04.005>
- Khan A, 2009. *Veterinary Clinical Pathology*. 1st Ed. University of Agriculture Press, Faisalabad, Pakistan.
- Lackner R, 1988. Oxidative stress in fish by environmental pollutants. *Fish Ecotoxicology* 86: 203–224. https://doi.org/10.1007/978-3-0348-8853-0_6
- Landers TF, Cohen B, Wittum TE and Larson EL, 2012. A review of antibiotic use in food animals: perspective, policy, and potential. *Public Health Reports* 127: 4–22. <https://doi.org/10.1177/003335491212700103>
- Limbu SM, Zhou L, Sun SX, Zhang ML and Du ZY, 2018. Chronic exposure to low environmental concentrations and legal aquaculture doses of antibiotics cause systemic adverse effects in Nile tilapia and provoke differential human health risk. *Environment International* 115: 205–219. <https://doi.org/10.1016/j.envint.2018.03.034>
- Mi C, Teng Y, Wang XF, Yu HY, Huang ZX, Zong WS and Zou L, 2018. Molecular interaction of triclosan with superoxide dismutase (SOD) reveals a potentially toxic mechanism of the antimicrobial agent. *Ecotoxicology and Environmental Safety* 153: 78–83. <https://doi.org/10.1016/j.ecoenv.2018.01.055>
- O'Brown MN, Pfau SJ and Gu CH, 2018. Bridging barriers: a comparative look at the blood-brain barrier across organisms. *Genes and Development* 32: 466–478. <https://doi.org/10.1101/gad.309823.117>
- Park JC, Han J, Lee MC, Seo, JS and Lee JS, 2017. Effects of triclosan (TCS) on fecundity, the antioxidant system, and oxidative stress-mediated gene expression in the copepod *Tigriopus japonicus*. *Aquatic Toxicology* 189: 16–24. <https://doi.org/10.1016/j.aquatox.2017.05.012>
- Paul T, Kumar S, Shukla SP, Pal P, Kumar K, Poojary N, Biswal A and Mishra A, 2020a. A multi-biomarker approach using integrated biomarker response to assess the effect of pH on triclosan toxicity in *Pangasianodon hypophthalmus* (Sauvage, 1878). *Environmental Pollution* 260: 114001. <https://doi.org/10.1016/j.envpol.2020.114001>
- Paul T, Shukla SP, Kumar K, Poojary N and Kumar S, 2020b. Effects of Temperature and pH on Acute Toxicity of Triclosan in *Pangasianodon hypophthalmus* (Sauvage, 1878). *Science of The Total Environment* 668: 104–114. <https://doi.org/10.1016/j.scitotenv.2019.02.443>
- Reimschuessel R and Williams D, 1995. Development of new nephrons in adult kidneys following gentamicin-induced nephrotoxicity. *Renal Failure* 17: 101–106. <https://doi.org/10.3109/08860229509026246>
- Reimschuessel R, Chamie SJ and Kinnel M, 1996. Evaluation of gentamicin-induced nephrotoxicosis in toadfish. *Journal of the American Veterinary Medical Association* 209: 137–139.
- Rodricks JV, Swenberg JA, Borzelleca JF, Maronpot RR and Shipp AM, 2010. Triclosan: A critical review of the experimental data and development of margins of safety for consumer products. *Critical Reviews in Toxicology* 40: 422–484. <https://doi.org/10.3109/10408441003667514>
- Rodrigues S, Antunes SC, Nunes B, Correia AT, 2019. Histopathological effects of the antibiotic erythromycin on the freshwater fish species *Oncorhynchus mykiss*. *Ecotoxicology and Environmental Safety* 181: 1–10. <https://doi.org/10.1016/j.ecoenv.2019.05.067>
- Sahu V, Karmakar S, Kumar S, Shukla S and Kumar K, 2018. Triclosan toxicity alters behavioral and hematological parameters and vital antioxidant and neurological enzymes in *Pangasianodon hypophthalmus* (Sauvage, 1878). *Aquatic Toxicology* 202: 145–152. <https://doi.org/10.1016/j.aquatox.2018.07.009>
- Sharma P, Chadha P and Saini HS, 2019. Tetrabromobisphenol A induced oxidative stress and genotoxicity in fish *Channa punctatus*. *Drug and Chemical Toxicology* 42: 559–564. <https://doi.org/10.1080/01480545.2018.1441864>
- Tao S, Wang L, Zhu Z, Liu Y, Wu L, Yuan C, Zhang G, Wang Z. 2019. Adverse effects of bisphenol A on Sertoli cell blood-testis barrier in rare minnow *Gobiocypris rarus*. *Ecotoxicology and Environmental Safety* 171: 475–483. <https://doi.org/10.1016/j.ecoenv.2019.01.007>
- Tasneem S and Yasmeen R, 2020. Biochemical changes in carbohydrate metabolism of the fish – *Cyprinus carpio* during sub-lethal exposure to biopesticide – Derisom. *Iranian Journal of Fisheries Sciences* 19: 961–973. <https://doi.org/10.22092/ijfs.2018.116876>

- Teplova VV, Belosludtsev KN and Kruglov AG, 2017. Mechanism of triclosan toxicity: Mitochondrial dysfunction including complex II inhibition, superoxide release and uncoupling of oxidative phosphorylation. *Toxicology Letters* 275: 108–117. <https://doi.org/10.1016/j.toxlet.2017.05.004>
- Vijitha CK, Asifa KP and Chitra KC, 2017. Assessment of genotoxic and hematological consequence of triclosan in the fish, *Oreochromis niloticus* (Linnaeus, 1758). *International Journal of Applied Research* 3: 101-109.
- Wang Q, Yang H, Yang M, Yu Y, Yan M, Zhou L, Liu X, Xiao S, Yang Y, Wang Y, Zheng L, Zhao HH and Li Y, 2019. Toxic effects of bisphenol A on goldfish gonad development and the possible pathway of BPA disturbance in female and male fish reproduction. *Chemosphere* 221: 235-245. <https://doi.org/10.1016/j.chemosphere.2019.01.033>

UN-CORRECTED PROOFS