



INTERNAL FIXATION TREATMENT OF MULTIPLE FRACTURES IN A DOG

Wei Chen ¹, Riquan Zhang², Xuan Wu¹, Qi Zhou¹, Zuwei Yang¹, Ziyuan Chen¹,
Mingchan Li¹, Jiacheng Yu¹, and Houyi Wu ^{2*}

¹Jiangxi Provincial Key Laboratory for Animal Health, Institute of Animal Population Health,
College of Animal Science and Technology, Jiangxi Agricultural University,
No. 1101 Zhimin Avenue, Economic and Technological Development District,
Nanchang 330045, Jiangxi, P. R. China;

²Ji 'an Livestock and Poultry Farm in Jiangxi Province, Ji 'an, 343016, Jiangxi, China

*Corresponding author: 519409914@qq.com

ABSTRACT

In order to learn the diagnosis and treatment of canine fractures, we treated a stray dog in a traffic accident. We observed and recorded the treatment process in detail with the purpose of providing reference for the treatment of fractures in dogs. The doctors conducted general examination, X-ray and a complete blood counts (CBCs) on the dog at a pet hospital at Nanchang, Jiangxi, China, and then immediately performed surgery on the site of the severe fractures. Intramedullary nail and bone plate, and intramedullary nail and steel wire were respectively used for internal fixation of transverse fracture of femur of left hind-limb and oblique fracture of tibia of right hind-limb. Subsequently, suitable splint was used for external fixation, and the rest of the fractures healed on their own. After three months of postoperative nursing and massage, the internal fixation material was removed. The results showed that the dog had a good recovery. This paper has provided case study and a clinical practical reference for the diagnosis and treatment of complex multiple fractures.

Keywords: Canine fracture; Internal fixation; External fixation.

Article History (2020-0929) || Received: 7-Sep-2020 || Revised: 22 Sep 2020 || Accepted: 15 Oct 2020 || Published Online: 02 Nov 2020

1. INTRODUCTION

Fracture is a kind of mechanical injury caused by pathological factors or external forces on the continuity and integrity of bone tissue, which is often accompanied by varying degrees of damage to the surrounding tissue (Gilbert et al. 2017). The types of fractures include transverse type, short oblique type and comminuted type. Fractures often occur in the long bones of the extremities. There are many causes of dog fractures, such as the impact of a car, jumping or falling from a high place, twisting and flickering when running and jumping. External force impact is a common cause of dog fracture in clinic. The occurrence of fractures is also related to dog breeds (Sanchez et al. 2020). Generally, dogs with small bones and small physique are more likely to have traumatic fractures. The location of a fracture also has some characteristics, such as common fracture of hind-limb, simultaneous fracture of radius and ulna in dogs, transverse fracture in the middle or distal end of bone, and oblique fracture. Clinically, the fracture of dogs is mainly diagnosed by X-ray examination. An X-ray can not only diagnose the fracture, but also clearly show the shape of the fracture and the displacement of the bone at the fracture. With the help of an X-ray, it is convenient to make an operational procedure, and understand the anastomosis of the broken end of the bone after the operation and the healing of the fracture after nursing. Mild cracked fracture without obvious displacement can be treated conservatively. When fracture occurs, the growth factor can accelerate bone healing (López et al. 2019). However, when the fracture is more serious and can't heal by itself, it needs to be repaired by internal fixation. The bones of dogs have a strong ability of regeneration, as long as the broken end of the fracture is anastomosed and fixed with internal fixation materials during the operation and leave a suitable gap. Generally, there is no need to use bone grafting drugs. However, if the fracture is not treated in time or treated improperly, it may cause a series of complications (Hayes et al. 2020).

In recent years, with an increasing number of pets, the domestic pet diagnosis and treatment industry is in the stage of rapid development. In the clinical treatment of canine fractures, it is common to combine internal fixation with open diagnosis rather than simple external fixation. Dogs that can't undergo surgery due to excessive fineness of bone or organ dysfunction caused by disease generally do not use external fixation. Combined with the case data of a pet hospital, through the observation and analysis of a series of processes of dog diagnosis, treatment and nursing, this paper provides some reference for the treatment of dog fractures with internal fixation.

2. MATERIALS AND METHODS

2.1. Clinical information

The dog was a two-year-old male Chinese pastoral dog with a body weight of 7 kg. We carried out clinical and laboratory tests on the dog. The state of the dog was preliminarily judged by observing the active state of the dog and measuring whether the pulse, heart rate and body temperature were normal or not. X-ray examination and CBCs were performed before the operation.

2.2. Preoperative preparation and anesthesia

After shaving the dog, atropine sulfate (0.03 ml/kg, Shanghai Quanyu Biotechnology Animal Pharmaceutical Co Ltd, China) was injected subcutaneously. After 15 min, propofol (0.4 mg/kg, Libang Pharmaceutical Co Ltd, China) was injected intravenously to induce anesthesia. When the dog was under anesthesia, the doctor's assistant used gauze strips to open the dog's upper and lower jaw, held the laryngoscope in the left hand and intubates the trachea in the right hand. Anesthetic machine was turned on to release isoflurane to maintain and regulate the state of anesthesia. Attention was paid to detect the heart rhythm and respiration of the affected dogs. The surgical part of the hind-limb of the affected dog was routinely disinfected and the operation was carried out after the dog's signs were stable.

2.3. Surgical pathway

Regarding the treatment of left hind-limb femoral fracture, we used the femoral shaft surgical approach, starting from the level of the greater trochanter, and along the anterolateral edge of the femoral shaft to the patella. We paid attention to avoid larger skin vessels, cut open the skin horizontally, and then bluntly separated the subcutaneous fat layer and the superficial fascia layer downward. The broad fascia was cut along the anterior edge of the biceps femoris, then the muscle was bluntly separated and pulled backward to expose the broken end of the femur. The inactivated tissue and bone fragments were removed with periosteal exfoliator and edentulous forceps, and the congestion at the broken end was washed with warm normal saline. The intramedullary nail was trimmed at an appropriate length. We reversed the nail along the broken end of the proximal femur, took the nail out of the skin at the greater trochanter of the femur, and then entered the nail forward to the distal end of the femur. The two broken ends of the femur were reduced with bone holding forceps, anastomosed to the normal physiological position, and the lateral femur was fixed with a bone plate (Fig. 1), and 6 screws were placed in the drilled bone. After washing the wound cavity with warm saline again, antibiotics were placed in the wound cavity. We used needle holding forceps, a round needle and absorbable sutures to close the tissue, cut off the intramedullary nail at the greater trochanter, closed the skin with non-absorbable sutures and a triangular needle, and gently pulled the skin back to the subcutaneous needle.

Regarding the treatment of tibiofibular fracture of the right hind-limb, we started from the anterolateral part of the proximal lateral condyle of the tibia. An 8cm skin incision was made to the distal external condyle, and the subcutaneous tissue and fascia were separated. We pulled the tibialis anterior muscle and extensor digitorum longus muscle backward to expose the broken end of the tibial fracture (Fig. 1). We peeled off with a periosteal exfoliator and rinse with warm normal saline to remove the contusion tissue, bone fragments and blood clots at the broken end. The fracture of the broken end was reduced and anastomosed to the normal physiological position, and the intramedullary nail was inserted in reverse along the broken end of the proximal tibia, out of the skin at the front of the tibia, and then pushed forward to the distal end of the tibia. Finally, two sites of the broken end of the fracture were fixed with steel wire. Fibula fracture does not need to be fixed. The wound cavity was washed with warm normal saline, antibiotics were placed in the wound cavity, the absorbable sutures of needle holding forceps and round needles were used to close the muscle tissue, and the skin was fitted to cut off the intramedullary needle at the anterior end of the tibia. We closed the skin intermittently with a triangular needle and non-absorbable sutures, gently pulled the skin and putted the intramedullary needle under the skin.

2.4. Postoperative nursing

In the process of recovery of the affected dog, a variety of vitamins and bovine milk calcium glue should be added appropriately. Liquid food was provided 6 hours after the operation. Subcutaneous injection of Butorphanol (0.1mL/kg, Hengrui Pharmaceutical Co Ltd, China) to relieve pain. Cefotaxime sodium was injected intravenously within 3 days to prevent secondary infections. We applied iodophor to the surgical site every day, cleaned the exudate and changed the gauze regularly. Four days later, the sick dog was occasionally seen standing up. A week later, the swollen part of the limb is subcutaneously injected with Enrofloxacin (0.1 mL/kg, Jiangxi Boda Animal Health Products Co Ltd, China) to control the infection, and we paid attention to keep the operation site dry. On the 10th day after the operation, the skin suture healed well and the swelling of the affected limb had been reduced, but the dog was still unable to move. The indexes of CBCs are normal. We massaged the affected limb every day to prevent muscle atrophy. The non-absorbable suture was removed on the 14th day after operation. On the 30th day,

it was observed that the motor function of the affected dog was still limited. On the 100th day after operation, the affected dog had generally recovered the motor function, and the two affected limbs could bear the weight well. An X-ray showed that the fracture site healed well and the fracture line basically disappeared. The internal fixation materials such as intramedullary needle and steel plate were removed by reoperation.

3. RESULTS

3.1. The results of clinical examination

The sick dog was in a poor mental state when he was sent to the hospital. His body temperature was 39.1°C, heart rate was 160 bpm, and respiration rate was 40 bpm. The visual mucosa was slightly pale and the refilling time of the mucosa was normal. The hind-limb was paralyzed, the thigh of the left hind-limb was swollen, and there was no open wound. There was no obvious abdominal pain and no visceral bleeding on palpation. The initial diagnosis was fracture.

3.2. Results of X-ray examination

In Fig. 2, it can be seen that there are many fractures in the whole body, and the fractures of the middle femur of the left hind-limb and the middle tibiofibula of the right hind-limb are more serious.

3.3. Results of a complete blood count

A complete blood count was conducted (Table 1). The total number of white blood cells, hematocrit and platelet values increased, while the number of red blood cells decreased. The results showed that the affected dogs had inflammatory reaction, hemorrhagic anemia and mild dehydration. In addition, there was a possibility of internal bleeding or soft tissue contusion at the fracture site.

3.4. Prognosis

The dogs were examined by an X-ray 100 days after the operation (Fig. 3). The fracture site had a good prognosis and the fracture line basically disappeared.

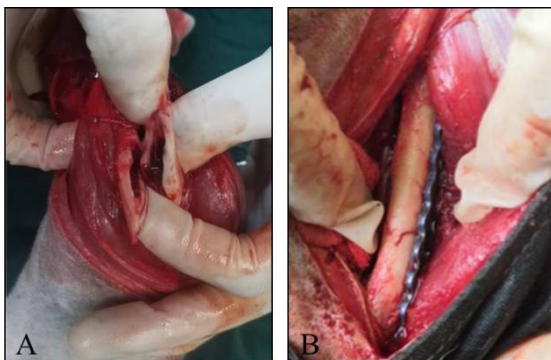


Fig. 1: A) Reconstruction and fixation of left hind-limb femur and B) The right hind-limb exposed the broken end of the tibia.

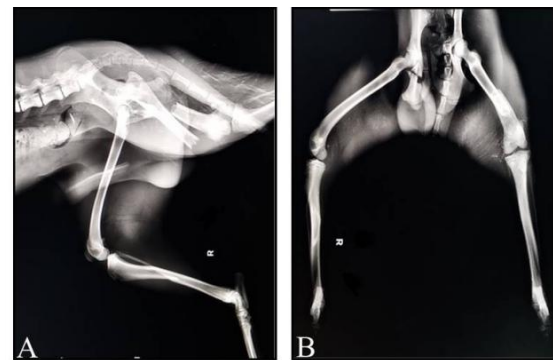

Fig. 2: A) Lateral observation of femoral and tibiofibular fractures of hind-limb and B) Frontal observation of femoral and tibiofibular fractures of hind-limb.

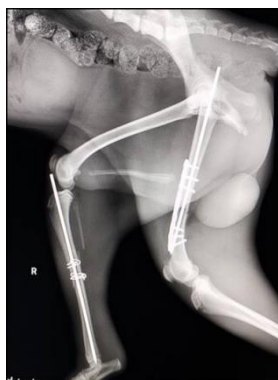

Fig. 3: An X-ray 100 days after the operation of hind-limb of the dog.

Table 1: Results of a complete blood count

Indices	Units	Result	Reference Values
Leukocytes	×10 ⁹ /L	21.9↑	6.0-17.0
Neutrophils	×10 ⁹ /L	14.7↑	3-12
Lymphocytes	×10 ⁹ /L	1.56	1-4.8
Monocytes	×10 ⁹ /L	0.4	0.2-1.5
Erythrocytes	×10 ⁹ /L	5.2↓	5.5-8.5
Hematocrit	%	59.1↑	39-56
Hemoglobin	g/L	148	110-190
Platelets	×10 ⁹ /L	563↑	200-500
Mean platelet volume	fl	8.3	3.9-11.1

4. DISCUSSION

There are a variety of causes of fractures, and traffic accident is an important cause of fractures. Internal fixation and external fixation are commonly used in the clinical treatment of fractures. Internal fixation requires certain surgical conditions and techniques, resulting in greater tissue damage and higher fees. External fixation has the characteristics of simple operation, less tissue injury, low infection risk and low cost, so that external fixation is generally used to treat low-position fractures in clinic. The dog was sent to hospital after a car accident. According to the X-ray, there were multiple fractures. The doctor diagnosed that the severe fractures of the tibia of the right hind-limb and the femur of the left hind-limb should be treated surgically, and the rest of the fractures such as ribs and pelvis could be recovered by themselves. A complete blood count can accurately judge the changes of blood indexes, and some studies have shown that some of these indexes are related to the prognosis of fracture (Milani et al. 2012). According to the results of CBCs, we found that the total number of white blood cells, hematocrit and platelet values increased and the number of red blood cells decreased. It was inferred that there was no visceral rupture, and there were mild internal bleeding, dehydration, stress and inflammation. During the operation, the tibia was fixed with intramedullary nail and steel wire, and the femur was fixed with intramedullary nail and bone plate. Considering the overall condition of the affected dog, propofol and isoflurane were selected to induce anesthesia and respiratory anesthesia respectively. Body fluids were constantly replenished in the process. After more than 3 months of treatment and postoperative nursing, the fracture site healed well.

After the occurrence of fractures in dogs, they should be treated as soon as possible. If the treatment is delayed, it will increase the difficulty of the operation and affect the operation. After the occurrence of open fractures, the operation should be carried out within 8 hours, and the operation site should be thoroughly cleaned and disinfected before the operation in order to prevent infection. The application of X-ray examination of fractures is very important. The damage of the fracture site can be observed directly and clearly by taking X-ray at the first time, and the corresponding operational procedure can be made. Commonly used materials for internal fixation are bone plate, metal screw, intramedullary nail, steel nail and so on, which can fix the broken bone and have a better ability to maintain the normal physiological shape of the broken bone to heal (Boero Baroncelli et al. 2012). However, the removal of these internal fixation materials has a high risk, such as slow callus formation at the bone plate joint or insufficient toughness of the new bone at the broken end (Arora et al. 2007; Maehara et al. 2013). Some medical diseases such as diabetes and cardiovascular diseases lead to osteoporosis and increase the risk of secondary fractures when the material is removed (Majumdar et al. 2012). If the internal fixation material is not removed, the implant may break, infect or destroy the original tissue. The X-ray results after the removal of the intramedullary nail in this case showed that there was a low-density shadow in the location of the original intramedullary nail, indicating that the intramedullary nail destroyed the original tissue. Under careful monitoring, the complications of external fixation splint are mild, which can be used as the main method of temporary support and fixation of the fracture site. For small dogs, reasonable simple external fixation can also achieve a better treatment effect, but compared with large dogs, external fixation is prone to slippage, so that internal fixation is the best choice for the treatment of this type of fractures. The common pathogen of infection after orthopedic surgery is *Staphylococcus aureus*, and infection will have a great adverse effect on the prognosis and recovery (Khan et al. 2008; Metsemakers et al. 2018). After the operation, we should not only conduct good anti-inflammation tasks, but also pay close attention to the mental state of the affected dogs. Relieving postoperative pain can help dogs to recover well from fractures (Dimopoulou et al. 2017).

Conclusion: The operator is proficient in the professional knowledge of fracture internal fixation, which is very important for the operation. Moreover, careful postoperative care helps to heal the fracture site quickly and prevent secondary infection.

Authors' contributions: Houyi WU conceived and designed experiments. Wei Chen, Riquan Zhang, Xuan Wu, Qi Zhou, Zuhui Yang, Ziyuan Chen, Mingchan Li and Jiacheng Yu was involved in the operation. Wei Chen and Riquan Zhang prepared the draft of the manuscript. All authors critically revised the manuscript and approved of the final version.

Conflict of Interest Statement: The authors declare that there are no conflicts of interest.

ORCID

Wei Chen: <https://orcid.org/0000-0002-0283-1903>

Houyi Wu: <https://orcid.org/0000-0001-9632-7056>

REFERENCES

- Arora R, Lutz M, Hennerbichler A, Krappinger D, Md DE and Gabl M, 2007. Complications following internal fixation of unstable distal radius fracture with a palmar locking-plate. *Journal of Orthopaedic Trauma* 21: 316-322. <https://doi.org/10.1097/bot.0b013e318059b993>
- Boero Baroncelli A, Peirone B, Winter MD, Reese DJ and Pozzi A, 2012. Retrospective comparison between minimally invasive plate osteosynthesis and open plating for tibial fractures in dogs. *Veterinary and Comparative Orthopaedics and Traumatology* 25: 410. <https://doi.org/10.3415/VCOT-11-07-0097>
- Dimopoulou I, Anagnostou TL, Prassinou NN, Savvas I and Patsikas M, 2017. Effect of intrafragmentary bupivacaine (haematoma block) on analgesic requirements in dogs undergoing fracture repair. *Veterinary Anaesthesia and Analgesia* 44: 1189-1197. <https://doi.org/10.1016/j.vaa.2017.01.005>
- Gilbert ED, Lewis DD, Townsend S and Kim SE, 2017. Comparison of two external fixator systems for fracture reduction during minimally invasive plate osteosynthesis in simulated antebrachial fractures. *Veterinary Surgery* 46: 971-980. <https://doi.org/10.1111/vs.12687>
- Hayes MA, Jemilo S, Muir P, Sullivan R and Bleedorn JA, 2020. Pathologic fracture healing after femoral limb salvage in a dog. *Australian Veterinary Journal* 98: 84-89. <https://doi.org/10.1111/avj.12899>
- Khan MS, Ur RS, Ali MA, Sultan B and Sultan S, 2008. Infection in orthopedic implant surgery, its risk factors and outcome. *Journal of Ayub Medical College, Abbottabad: JAMC*, 20: 23-25.
- López S, Vilar J M, Sopena JJ, Damià E, Chicharro D, Carrillo JM, Cuervo B and Rubio M, 2019. Assessment of the efficacy of platelet-rich plasma in the treatment of traumatic canine fractures. *International Journal of Molecular Sciences* 20: 1075. <https://doi.org/10.3390/ijms20051075>
- Maehara T, Moritani S, Ikuma H, Shinohara K and Yokoyama Y, 2013. Difficulties in removal of the titanium locking plate in Japan. *Injury* 44: 1122-1126. <https://doi.org/10.1016/j.injury.2013.01.042>
- Majumdar SR, Ezekowitz JA, Lix LM and Leslie WD, 2012. Heart failure is a clinically and densitometrically independent risk factor for osteoporotic fractures: Population-based cohort study of 45,509 subjects. *The Journal of Clinical Endocrinology & Metabolism* 97: 1179-1186. <https://doi.org/10.1210/jc.2011-3055>
- Metsemakers WJ, Morgenstern M, McNally MA, Moriarty TF, McFadyen I, Scarborough M, Athanasou NA, Ochsner PE, Kuehl R, Raschke M, Borens O, Xie Z, Velkes S, Hungerer S, Kates SL, Zalavras C, Giannoudis PV, Richards RG and Verhofstad M, 2018. Fracture-related infection: A consensus on definition from an international expert group. *Injury* 49: 505-510. <https://doi.org/10.1016/j.injury.2017.08.040>
- Milani TAP, Rodrigues L, Chiattoni C and Luz JGC, 2012. Changes in complete blood count in patients with surgically treated facial fractures. *Journal of Craniofacial Surgery* 23: e587-e591. <https://doi.org/10.1097/SCS.0b013e31826bf030>
- Sanchez Villamil C, Phillips ASJ, Pegram CL, O'Neill DG and Meeson RL, 2020. Impact of breed on canine humeral condylar fracture configuration, surgical management, and outcome. *Veterinary Surgery* 49: 639-647. <https://doi.org/10.1111/vsu.13432>